




Flood is AGS National Clinician of the Year for 2019

Celebrating the award with a
“Yoda Best Geriatrician” mug at
a surprise celebration: Emily
Simmons, RN, and Dr. Katrina
Booth with Dr. Kellie Flood.



ASN Announces Allon as
Editor-in-Chief of New Online
Journal *Kidney360*

Michael Allon, MD
Professor, Nephrology

It Gets Worse Before It Gets Better: Delayed Post Hypoxic Leukoencephalopathy

Stephen Stuart, MD · Maddie Bender, MS · Starr Steinhilber, MD, MPH



Learning Objectives

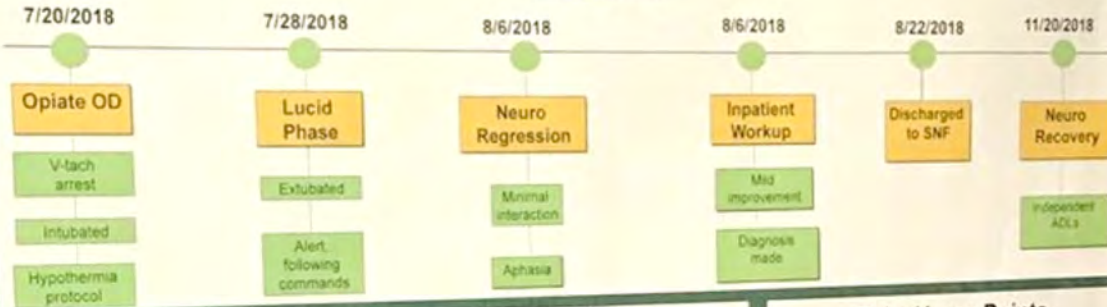
1. Define the clinical pattern of diffuse post-hypoxic leukoencephalopathy (DPHL)
2. Emphasize the importance in recognizing a reversible cause of encephalopathy

Background

- Rare demyelinating syndrome observed following cerebral hypoxic event
- Clinically characterized by lucid period (7-21 days) followed by abrupt onset of neurologic symptoms
- Diagnosed based on clinical timing, symptoms, imaging, and exclusion of other diagnoses
- Radiographical findings include cerebral white matter demyelination
- Treated with supportive management with many patients making significant recovery

Case Presentation

Timeline



Exam Findings

Reflexes	Hypereflexive
Speech	Mutism
Tone	Rigid
Frontal release signs	Snout reflex
Behavior	Pathologic laughter, apathy

Patient Workup

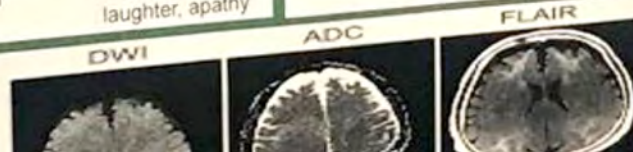Toxins	(+) benzos, (-) ETOH
Metabolic	TFT, LFT, A1C, NH4, BUN, CO2 within normal limits
Infectious	(-) blood cultures, urine cultures, HIV, RPR, Hep C, CSF cultures
Vasculitides	CRP within normal limits, ESR slightly elevated, RF neg, cryoglobulin, ANA neg, Thiamine, B12 WNL
Nutritional	
Neurologic	EEG: generalized slowing CT head: possible infarcts MRI: multiple demyelination lesions

Take Home Points

- Consider DPHL in patients who experience delayed neurologic symptoms following a prolonged hypoxic event
- MRI findings include diffuse white matter lesions in the cortex
- Important to recognize DPHL to potentially avoid extensive, invasive work up
- Treatment includes supportive care and rehabilitation

References

1. King F, Morra NA, Schmahmann JD. Delayed Posthypoxic Leukoencephalopathy: Improvement with Antioxidant Therapy. *Case Rep Neurol*. 2015;7(3):242-8.
2. ...
3. ...



Stuart Presents Case at National SGIM Meeting
Stephen Stuart, MD (PGY3) demonstrates “It Gets Worse Before It Gets Better”



Bittner Receives National Lipid Association's Distinguished Achievement Award

Vera Bittner, MD
Professor, Cardiovascular Disease

Current Oncology Reports

Godby and
Williams publish
on immunotherapy
in older adults
with cancer.




Rich Godby, MD
PGY-2



Grant Williams, MD
Assistant Professor, Hematology
and Oncology



Farewell to the 2018-2019 Chief Medical Residents
L to R: Drs. Joanna Zurko, Jeremy Walker, James Barrios and KeAndrea Titer



New Faculty Spotlight: Kirk Russ, MD

Dr. Russ joins the faculty in Gastroenterology and Hepatology after completing a chief year and fellowship here at UAB. He will focus on clinical practice, specifically IBD.

Kirk Russ, MD

Assistant Professor,
Gastroenterology and Hepatology

Medical Grand Rounds

Wednesday,
June 5, 2019

12:00 P.M. in
Margaret Cameron
Spain Auditorium

*Deane K. Corliss Palliative &
Supportive Care Lecture Series*

Cultural Considerations for Palliative Care



Monica L. Baskin, PhD

Vice Chair for Culture and Diversity,
UAB Department of Medicine

Professor,
UAB Division of Preventive Medicine
